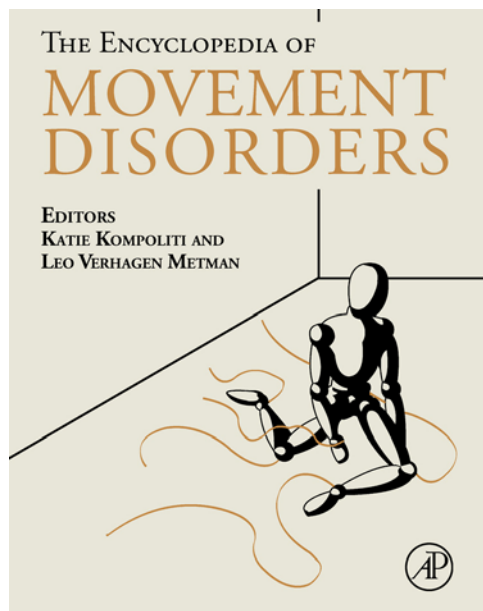


Provided for non-commercial research and educational use.  
Not for reproduction, distribution or commercial use.

This article was originally published in *Encyclopedia of Movement Disorders*, published by Elsevier. The attached copy is provided by Elsevier for the author's benefit and for the benefit of the author's institution. It may be used for non-commercial research and educational use, including (without limitation) use in instruction at your institution, distribution to specific colleagues who you know, and providing a copy to your institution's administrator.



All other uses, reproduction and distribution, including (without limitation) commercial reprints, selling or licensing of copies or access, or posting on open internet sites, personal or institution websites or repositories, are prohibited. For exception, permission may be sought for such use through Elsevier's permissions site at:

<http://www.elsevier.com/locate/permissionusematerial>

Tuite P J and Konczak J (2010) Cortical Sensory Dysfunction and the Parietal Lobe. In: Kompoliti K, and Verhagen Metman L (eds.) *Encyclopedia of Movement Disorders*, vol. 1, pp. 254-257 Oxford: Academic Press.

that these findings suggest an aberrant function in the cortical GABAergic inhibitory circuits.

Sensory cortex hyperexcitability also appears to be important in the pathophysiology of myoclonus. Measuring cortical potentials in response to peripheral sensory stimulation is commonly performed to study the integrity of the central nervous system and the technique is commonly referred to as SEPs. 'Giant' SEPs (P25–P33) are known to occur in patients with cortical myoclonus and suggest hyperexcitability of the sensory cortex. Similar to the TMS paired pulse paradigm, SEP can also be administered in this fashion. SEP suppression is seen at an ISI of  $\leq 100$  ms in healthy individuals. In some patients with myoclonus, suppression was not observed, and in some cases, facilitation was noted suggesting a dysfunction of the sensory cortical inhibitory circuits leading to hyperexcitability in the cortex.

There is ample evidence to suggest aberrant excitability in the motor and sensory cortices in patients with cortical myoclonus. The underlying pathology though unclear is being studied in great detail using advances in electrodiagnostic techniques. Recent evidence suggests that interhemispheric interactions between the motor cortices appear to be important. The molecular and biochemical abnormalities underlying the hyperexcitability are yet to be defined.

## Treatment

The pharmacological management of cortical myoclonus includes Clonazepam, valproic acid, primidone, and piracetam. Newer agents such as Levetiracetam (an analogue of piracetam) and  $\gamma$ -hydroxybutyric acid (GHB) are also effective antimyoclonic therapies.

See also: Myoclonus; Myoclonus, Epileptic.

## Further Reading

- Shibasaki H (2006) Neurophysiological classification of myoclonus. *Clinical Neurophysiology* 36: 267–269.
- Toro C and Hallett M (2004) Pathophysiology of myoclonic disorders. In: Watts RL and Williams WC (eds.) *Movement Disorders: Neurologic Principles and Practice*, 2nd edn. McGraw-Hill.

## Relevant Websites

[www.movementdisorders.org](http://www.movementdisorders.org) – Movement Disorder Society.

# Cortical Sensory Dysfunction and the Parietal Lobe

**P J Tuite and J Konczak**, University of Minnesota, Minneapolis, MN, USA

© 2010 Elsevier Ltd. All rights reserved.

## Glossary

**Astereognosia** – Inability to recognize things by touch.

**Exteroception** – Perception of stimuli originating outside the body, for example, vision, touch, olfaction.

**Interoception** – Perception of stimuli originating inside the body, for example, hunger, thirst, visceral sensations.

**Proprioception** – Perception of the position and movement of body or its parts.

**Pseudoathetosis** – Involuntary writhing movements due to proprioceptive deficits.

**Simultanagnosia** – Inability to synthesize visual information into a complete picture.

## Introduction

The parietal lobe is part of a sensory system comprising peripheral receptors, neural pathways, and neurons of several supraspinal centers (cerebellum, basal ganglia, parietal lobe) that process visual and somatosensory information. The somatosensory modalities include proprioception (e.g., perception of body and limb positions), interoceptive sensory modalities such as temperature and pain perception, and touch. Classically, touch has been defined as an exteroceptive sense. However, in recognition that touch perception is based on several modalities, the term somatic senses is also commonly used. It is known that the parietal lobes mediate exteroceptive and proprioceptive perception, while interoceptive sensations are also associated with activations of the right insular cortex. This article will focus primarily on the parietal

lobe, and the effect of parietal lobe lesions on cognitive, perceptual, and motor function.

One of the primary roles of the parietal cortex lies in the integration of somatosensory and visual information that is needed for movement planning and control. In addition, specific areas of the parietal lobe are relevant for cognitive processes such as reading comprehension, and logical and mathematical thinking. One of the first comprehensive accounts of parietal lobe function was published in 1953 by the British neurologist Macdonald Critchley whose insights were based largely on the study of patients with parietal lesions. Since then, numerous researchers attempted to correlate behaviors with parietal and subcortical neural activity in humans and animals using an array of psychophysical, electrophysiological, and brain imaging techniques.

### Neuroanatomical Subdivisions of the Parietal Lobe

The parietal lobe is a region of the cerebral cortex between the frontal and occipital lobes. Its principal areas include the *primary somatosensory cortex* (PSC) comprising the post-central gyrus (Brodmann areas 1, 2, 3), the superior parietal lobule (areas 5 and 7), the parietal operculum (area 43), the supramarginal gyrus (area 40), and the angular gyrus (area 39). Two functional zones of the parietal lobe can be distinguished: an anterior zone (Brodmann's areas 1, 2, 3, 43) and a posterior zone which includes the remaining areas. The posterior zone is also known as the *posterior parietal cortex* (PPC). The PPC receives afferent projections from the somatosensory cortex, the premotor and motor cortices. In addition, area 7b of the PPC receives visual, somesthetic, proprioceptive, auditory, vestibular signals, as well as input from oculomotor and cingulate regions. The PPC has efferent projections to the prefrontal area 46, the frontal motor cortical areas (4, 6, and 8), the cingulate gyrus, the basal ganglia, and the cerebellum. It is thought that the close reciprocal connections between prefrontal and parietal areas indicate the importance of this functional loop for the control of spatially guided behavior. This role is underlined by the existence of a major projection known as the *dorsal visual stream* which is believed to encode visual information in an egocentric reference system necessary for planning goal-directed movement.

In addition to distinguish between anterior and posterior parietal zones, a lateralization of functions between the right and left parietal lobes is found. Classically, the dominant (usually left) parietal lobe is involved in language and mathematical processing. Lesions of the left parietal lobe result in anomia, alexia, apraxia, agraphia, acalculia, finger agnosia, and right-to-left disorientation. *Gerstmann's syndrome* is characterized by the latter four features, and is often associated with an angular or a

supramarginal gyral lesion. The nondominant (typically right) parietal lobe is thought to be involved in spatial cognition. Lesions may result in contralateral neglect of a part of the body or space, constructional and dressing apraxia, difficulty with cube counting, impaired paper cutting, poor map reading, and astereognosia. When there are bilateral PPC lesions, features of *Balint's syndrome* may be present including *simultanagnosia* (inability to perceive more than one object at a time), *optic ataxia* (incoordination of hand and eye movement), and *optic apraxia* (inability to refixate the eyes voluntarily).

### Assessment of Parietal Lobe function

This section reviews some of the most common syndromes and clinical symptoms associated with parietal lobe damage such as apraxia, pseudoathetosis, cortical sensory loss, alien limb, and proprioceptive impairments.

Assessment of parietal function may include *somatosensory thresholds* (e.g., two-point discrimination/tactile sensation), *tactile recognition* (e.g., Sequin-Goddard form board and tactile patterns), *complex visual perceptual tasks* (e.g., Golin incomplete figures and Mooney closure test), *neglect*, *spatial relationships*, language (e.g., speech and reading comprehension using token tests), and *apraxia* (e.g., Kimura box and others discussed later). Another task which appraises frontal and parietal function as it relates to space is the Semmes test of extrapersonal space.

### Signs and Symptoms of Parietal Lobe Dysfunction

#### Neglect

The neglect syndrome, also called hemiagnosia-hemineglect or spatial neglect, is a neurological condition that manifests itself as a deficit in attention to and awareness of one side of the body or extrapersonal space. Most commonly, right parietal lobe damage leads to neglect of left-sided body parts and the left visual field. The impairments in attention to the left side can also occur in the auditory, proprioceptive, and olfactory domains. Right-sided neglect after left parietal damage is rare; likely reflecting the specialization of the left hemisphere for language.

#### Cortical Sensory Loss

Cortical sensory loss may appear to a patient or a clinician as a symptom due to a peripheral nerve, plexus, or root lesion with clinical symptoms such as numbness or tingling; however, on examination there are no primary sensory findings. There is, rather, impairment in joint position sense and two-point discrimination as well as findings of agrophesthesia and astereognosia.

### Pseudoathetosis and Cortical Sensory Dysfunction

Athetosis is a slow writhing movement that is not associated with sensory loss; whereas, pseudoathetosis is clinically indistinguishable from athetosis except for the additional finding of proprioceptive sensory changes. An assortment of different neuropathological lesions, including parietal pathology, can manifest as pseudoathetosis. From Salih's work, lesions in thalamic lemniscal projecting fibers to somatosensory S1 areas 2 and 3a result in altered discriminative sensations, for example, impaired proprioception with relative preservation of other sensory modalities.

### Alien Limb Phenomenon

There is controversy as to what constitutes an alien limb, but classically it is thought to include spontaneous movements that are minimally affected by volitional movement and may require restraint by the contralateral hand. Sometimes, pseudoathetosis or simple arm levitation is mistaken as a diagnostic sign of an alien limb.

### Proprioceptive Deficits in Parkinson's Disease (PD)

Kinesthesia refers to the conscious awareness of active and passive limb movements and limb or body position. It is often used interchangeably with the terms proprioception or muscle sense. Recent work has shown that individuals with mild to moderate PD have elevated thresholds for detecting changes in limb position, passive motion, and weight perception. In addition, PD patients may exhibit delayed proprioception-related potentials in the somatosensory cortex. While PD is known to affect the basal ganglia, it is also known that the basal ganglia receive massive parietal lobe input. Thus, the observed kinesthetic deficits may be understood as a parietobasal ganglia dysfunction.

### Apraxia

Apraxia is the loss of the ability to perform a motor task despite intact motor and sensory functions, and absence of a language disorder. A more specific definition of apraxia as obtained from Zadikoff and Lang and Geschwind and Damasio includes one or all of the following: 'failure to produce the correct movement in response to a verbal command, the failure to correctly imitate a movement performed by an examiner, the failure to perform a movement correctly in response to a seen object, and the failure to handle an object correctly.'

Contextual definitions of apraxia include ideomotor, limb, buccofacial, ideational, limb-kinetic, apraxia of speech and oculomotor apraxia, gait apraxia, and so on. The anatomical bases of these clinically distinct entities are, as expected, quite disparate. For the sake of this

discussion, we will focus primarily on ideomotor limb apraxia, ideational, and limb-kinetic apraxia.

*Limb-kinetic apraxia* is defined as the loss of hand and finger dexterity resulting from the inability to connect or isolate individual movements, and is accompanied by frontal and/or parietal pathology. *Ideomotor apraxia* is an impairment in goal-directed movement, and typically associated with left hemisphere frontoparietal lesions or/and accompanying pathology of deep white matter or parts of the basal ganglia (often striatal) fibers. For example, the person with ideomotor apraxia cannot show how to salute or brush his/her teeth. *Ideational apraxia* is defined as the impairment in knowing what to do, and there are accompanying content errors. The person is unable to create a plan for or appreciate the idea of a specific movement; for example, they cannot pick up a pen and write something. Pathology often involves the left parietotemporal and parietooccipital regions.

Apraxia may be assessed by the *Florida Apraxia Screening Test (FAST)*, and the revised version, *FAST-R*. The *FAST-R* battery consists of a variety of measures such as demonstration of gestures (e.g., how to salute, make a fist) and the use of tools (e.g., scissors, hammer, bottle opener, glass, comb and hair brush, salt shaker, saw, screwdriver, spoon), and signaling to others (e.g., stop, come here, go away, wave goodbye). A variety of errors (content, temporal, spatial) can clarify the degree of impairments. Other means to assess apraxia include the *De Renzi test*, *Goldenberg's test of apraxia* (which assesses impairment in imitation of meaningless gestures of hands, imitation of meaningless gestures of fingers, performance of meaningful gestures on demand, and pantomime of tool use), and the *Kimura box*.

In the realm of movement disorders, there are a variety of conditions that are accompanied by apraxia, the most notable of which is *corticobasal degeneration (CBD)* also (clinically) known as *corticobasal syndrome (CBS)*. Other conditions such as PD, progressive supranuclear palsy, Huntington's disease, dementia with Lewy bodies, and multiple system atrophy may also manifest apraxia. On the basis of the above clinical features, we will further discuss CBD/CBS which may prominently feature parietal dysfunction.

### Corticobasal Syndrome and Corticobasal Degeneration

CBS and CBD represent clinical and pathological entities, respectively, that are due to brain dysfunction involving the cortex (primarily the parietal lobes) and the basal ganglia; hence, this syndrome was formerly known as corticobasal ganglionic degeneration (CBGD). CBS represents a clinical entity with numerous possible underlying pathologies of which CBD is the most common pathology. Clinical diagnostic criteria proposed for CBS include the presence of all of the following: (1) insidious onset and progressive course; (2) no identifiable cause;

(3) cortical dysfunction (requiring the presence of one of the following: focal or asymmetrical ideomotor apraxia, alien limb phenomenon, cortical sensory loss, visual or sensory hemineglect, constructional apraxia, focal or asymmetric myoclonus, apraxia of speech/nonfluent aphasia); extrapyramidal dysfunction (at least one of the following: focal or asymmetrical appendicular rigidity without prominent and sustained response to levodopa or/and focal asymmetrical appendicular dystonia). Supportive findings from neuropsychological testing, MRI/CT scanning, or positron emission tomography (PET)/single photon emission computed tomography (SPECT) scanning may be helpful in making a clinical diagnosis.

Using diffusion-weighted imaging MRI methods, researchers have distinguished patients with a clinical diagnosis of CBS from other atypical parkinsonian syndromes (100% sensitivity and specificity) based on the presence of hemispheric asymmetry. Another study employing the MRI method, voxel-based morphometry, showed evidence of frontoparietal grey and subcortical grey matter atrophy in individuals who had CBD on autopsy.

The cause of CBS is unknown, and it is usually a sporadic condition. Rarely there have been cases where a genetic mutation or gene linkage has been found. Unfortunately, there is no obvious curative treatment for CBS, and management is primarily symptomatic.

## Summary

The parietal lobes are involved in the processing of visual and somatosensory information that is essential for movement planning and spatial cognition. The posterior parietal area is important in the visual guidance of movements of the limbs, head, and eyes along with mental planning of movements. Part of the parietal lobe appears to play a role in mathematical reasoning and reading comprehension. Dysfunction of the parietal lobes may result in features

such as cortical sensory loss, apraxia, which may also constitute features of a CBS.

See *also*: Alien Limb; Apraxia: Upper Limb; Athetosis; Corticobasal Degeneration.

## Further Reading

- Boeve BF, Lang AE, and Litvan I (2003) Corticobasal degeneration and its relationship to progressive supranuclear palsy and frontotemporal dementia. *Annals of Neurology* 54(supplement 5): S15–S19.
- Critchley M (1953) *The Parietal Lobes*. London: Edward Arnold.
- Geschwind N and Damasio AR (1985) Apraxia. In: Vinken PJ, Bruyn G, and Klawans HL (eds.) *Handbook of Clinical Neurology*, pp. 423–432. Amsterdam: Elsevier.
- Goldenberg G (2008) Apraxia and the parietal lobes. *Neuropsychologia* 47: 1449–1459.
- Goodale MA and Milner AD (1992) Separate visual pathways for perception and action. *Trends in Neuroscience* 15: 20–25.
- Heilman KM, Rothi LJ, and Valenstein E (1982) Two forms of ideomotor apraxia. *Neurology* 32: 342–346.
- Josephs KA, Whitwell JL, Dickson DW, et al. (2008) Voxel-based morphometry in autopsy proven PSP and CBD. *Neurobiology of Aging* 29: 280–289.
- Kolb B and Whishaw IQ (2008) The parietal lobes. In: Kolb B and Whishaw IQ (eds.) *Fundamentals of Human Neuropsychology*, 6th edn., pp. 345–369. New York: Worth Publishers.
- Maschke M, Gomez CM, Tuite PJ, and Konczak J (2003) Dysfunction of the basal ganglia, but not the cerebellum, impairs kinaesthesia. *Brain* 126: 2312–2322.
- Milner B (1980) Complementary functional specializations of the human cerebral hemispheres. In: Levy-Montalcini R (ed.) *Neurons, Transmitters, and Behavior*. Vatican City: Pontificiae academiae scientiarum scripta varia.
- Salih F, Zimmer C, and Meierkord H (2007) Parietal proprioceptive loss with pseudoathetosis. *Journal of Neurology* 254: 396–397.
- Schenkenberg T, Bradford DC, and Ajax ET (1980) Line bisection and unilateral visual neglect in patients with neurologic impairment. *Neurology* 30: 509–517.
- Semmes J, Weinstein S, Ghent L, and Teuber HL (1963) Correlates of impaired orientation in personal and extrapersonal space. *Brain* 86: 747–772.
- Sharp FR, Rando TA, Greenberg SA, Brown L, and Sagar SM (1994) Pseudochoreoathetosis: Movement associated with loss of proprioception. *Archives of Neurology* 51: 1103–1109.
- Zadikoff C and Lang AE (2005) Apraxia in movement disorders. *Brain* 128: 1480–1497.

## Cortical Tremor

**E A Shamim**, Movement Disorders Program at Georgetown University Hospital, Washington, DC, USA; National Institute of Neurological Disorders and Stroke at the National Institutes of Health, Bethesda, MD, USA

**C Toro**, National Institute of Neurological Disorders and Stroke at the National Institutes of Health, Bethesda, MD, USA

© 2010 Elsevier Ltd. All rights reserved.

## Glossary

**Myoclonus** – Brief, sudden, shock-like, involuntary movements caused by muscular contractions or inhibitions.

**Tremors** – Rhythmic oscillatory movements.

## Clinical Syndrome and Terminology

As a clinical syndrome, the term cortical tremor is most commonly associated with the condition now known as familial cortical myoclonic tremor with epilepsy (FCMTE). FCMTE has previously been referred to by many names, including autosomal dominant cortical